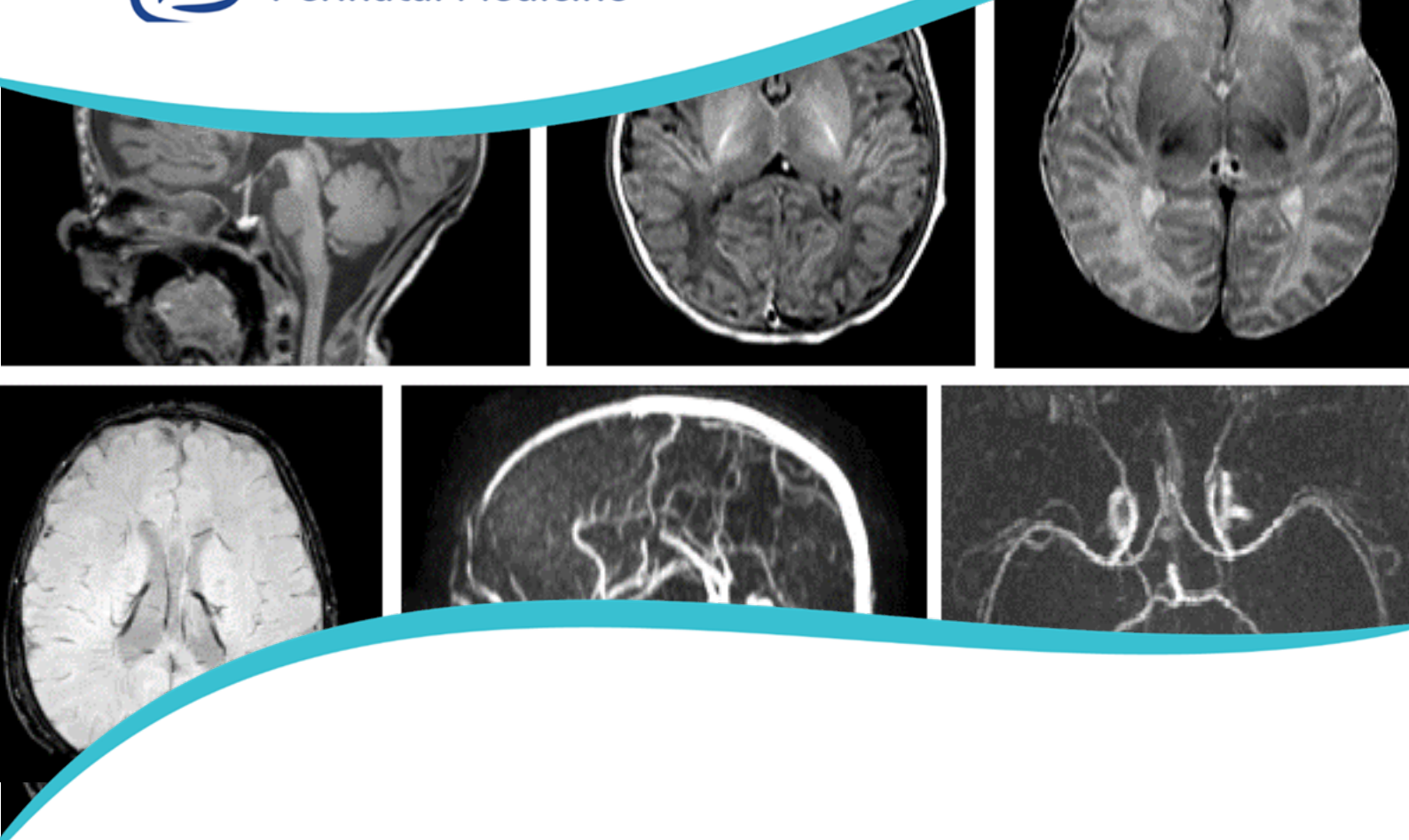




British Association of
Perinatal Medicine



Neonatal Brain Magnetic Resonance Imaging: Clinical indications, acquisition and reporting

A Framework for Practice

November 2023

In partnership with



Endorsed by



Contents

Executive Summary of Recommendations	3
Members of the working group	6
List of abbreviations.....	7
Terms of reference, audit standards and early notification scheme.....	8
Acquisition of neonatal MRI brain scans	10
Reporting of neonatal MRI brain scans.....	14
Term and near-term infants with neonatal encephalopathy & seizures.....	18
Antenatal abnormalities of the brain.....	22
Congenital and acquired infection.....	23
Neonatal hyperbilirubinaemia	25
Neonatal hypoglycaemia	26
Term infants with congenital heart disease	28
Term infants requiring extracorporeal membrane oxygenation	29
Preterm infants	30
References	32
Appendix 1a: Suggested key sequences and parameters for neonatal MR scans at 1.5T.....	37
Appendix 1b: Suggested key sequences and parameters for neonatal MR scans at 3.0T	37
Appendix 2: Example Reporting Proforma	38
Appendix 3: Development of the framework	40

Executive Summary of Recommendations

Background

The purpose of this document is to:

- Provide recommendations on clinical indications and timing for neonatal brain MRI.
- To promote best practice for acquiring and reporting neonatal brain MR images.

MR imaging of the newborn should be undertaken in a facility with experience in examining this patient group. Specialists with expertise in interpreting neonatal brain MRI should report these images; a network or regional approach can facilitate this.

Acquisition of neonatal MRI brain scans

- Acquiring a good quality brain scan is essential for accurate interpretation.
- Adequate time, training and resources should be available to ensure the infant is settled before and during the scan.
- The imaging protocol used needs to be optimised for the neonatal brain, suitable to detect a variety of conditions and tailored to the specific clinical history of the patient. To this end, a standard protocol for all babies may be useful.
- Communication, either formally through an MDT or informally between clinical teams (neonatologists, paediatric neurologists, neuroradiologists and radiographers) is important to ensure the scans are undertaken at a suitable time and with the appropriate sequences.
- Everyone involved in a neonatal MRI examination should know the risks within the MRI environment, including a strong magnetic field, and have received appropriate MR safety training.

Reporting of neonatal magnetic resonance imaging (MRI) brain scans

- Neonatal MRI brain scans should be reported by appropriately trained and qualified radiologists, with the report and images saved to the hospital PACS system.
- Depending on caseload, review of scans by more than one reporter is advocated, either through double reading/reporting of the scan or within the setting of MDT/clinical-radiological meetings. MDT meeting outcomes should be documented and supplied to the clinical teams.
- Where possible, the development of regional networks is recommended to share experience.
- The person requesting the scan should be aware of the limitations of the neonatal MRI scan, and the parents should be counselled accordingly.
- Parents should be informed of the results of the scan in a timely manner, following relevant discussion with neuroradiologists and/or paediatric neurologists. The results are best communicated by a member of the clinical team who is already known to the parents and has been involved in the care of their newborn infant.
- Parents should be counselled about the possibility of incidental findings, and services should have clinical pathways to manage actionable findings, e.g. multidisciplinary review and/or a follow-up scan.

Term and near-term infants with neonatal encephalopathy (NE) and/or seizures

- MRI is the imaging modality of choice for diagnostic imaging in NE and/or seizures.
- In newborn infants with NE and/or seizures in whom HIE is not suspected, ***MRI should not be delayed and should be undertaken as soon as it is safe and practical to do so.***
- MRI is useful in aiding diagnosis or cause of injury, timing of injury and prediction of neurological and developmental outcomes in newborns with hypoxic-ischaemic encephalopathy (HIE)
- In the case of newborn infants with NE and/or seizures, in whom there is a high suspicion of perinatal hypoxia-ischaemia, ***MRI should be undertaken between 4 and 14 days of life,*** taking care to interpret findings from the different sequences depending on the exact timing of the scan. If the infant is stable, early imaging (<6 days) can accurately identify injury, providing a complete and optimised good quality image dataset, including diffusion-weighted sequences, is acquired.

Antenatal abnormalities of the brain

Postnatal MRI may aid the diagnosis and identification of additional brain anomalies in neonates with suspected or confirmed antenatal brain abnormalities. The decision to scan an individual infant will depend on the results of specific antenatal investigations, the suspected diagnosis, and the need for further prognostic information.

Congenital and acquired infection

Imaging may be performed as soon as it is practical and safe to do so, to complement antenatal investigations where obtained. Imaging for acquired infection is advised in the presence of neurological signs and/or an abnormality on CrUS. It may be obtained as soon as the neonate is stable. Contrast administration may be warranted if there are concerns about complications of bacterial meningitis. MRA and MRV should be considered to exclude potential vascular complications. In babies who have failed hearing assessment, additional T2-weighted volumetric MR imaging of the cochleas and internal auditory canals provides valuable information and can aid in time-critical therapeutic decision-making.

Neonatal hyperbilirubinaemia

An MRI scan should be undertaken in a neonate with severe hyperbilirubinaemia associated with acute bilirubin encephalopathy and is best done as soon as it is safe and practical to do so. If neonatal imaging is considered normal, a repeat scan after six months of age may be useful in infants in whom there are neurological concerns. MRI cannot give information on the likelihood of hearing impairment.

Neonatal hypoglycaemia

While hypoglycaemia is associated with brain injury and neurodevelopmental impairment, the relationship between the severity and duration of hypoglycaemia and potential for injury is not straightforward. MRI should be undertaken in any neonate with seizures and/or reduced consciousness (lethargy, stupor or coma) and blood glucose <2.5mmol/l because of the risk of brain injury and neurodevelopmental impairment in this group. MRI is not required for transient low

blood glucose without abnormal neurological signs, although if the transient low blood glucose was $<1\text{mmol/l}$ and there is uncertainty about the documented presence/absence of acute neurological dysfunction, then clinicians should consider referral for MRI.

The pattern of injury acquired can aid prognosis for neurodevelopmental outcomes. However, a normal scan does not always exclude neurodevelopmental sequelae.

Term infants with congenital heart disease (CHD)

In infants with CHD pre- and post-operative MRI may help in defining the timing and extent of cerebral injury and should be considered in infants with moderate-severe cardiac lesions. MRI should be undertaken in all infants where there are abnormal neurological signs, unexplained dysmorphic features, known genetic anomalies associated with brain abnormalities, or evidence of parenchymal injury on CrUS.

Term infants undergoing extracorporeal membrane oxygenation (ECMO)

Infants undergoing ECMO are at risk of intracranial injury due to both the underlying pathology and complications of ECMO itself. Serial CrUS before and during ECMO is recommended but it may underestimate the degree of cerebral injury. There is only a limited amount of data relating acute brain injury following ECMO with long term neurodevelopmental problems. MRI following ECMO is recommended in infants in whom there are abnormal neurological signs or evidence of parenchymal brain injury on CrUS.

Preterm infants

MRI is not routinely indicated for all preterm infants as available evidence indicates it only adds modest value to CrUS for predicting outcomes, which has to be balanced against the logistics and cost of scanning. MRI should be considered if there is evidence of parenchymal injury on CrUS (large IVH, HPI, cPVL, PHVD, or focal pathology, including cerebellar lesions), abnormal neurological signs, or to aid diagnosis. The optimal timing for MRI of the preterm infant is 40-44 weeks postmenstrual age because this allows for assessment of brain maturation and myelination. In some circumstances, an earlier MRI may be beneficial if neurometabolic disease, congenital infection or CNS malformation are suspected, to assist surgical planning (e.g. for PHVD treatment), in infants with unexplained abnormal signs, or to inform end-of-life decisions.

Members of the working group

Chair: Dr Topun Austin, Consultant Neonatologist, Cambridge University Hospitals NHS Foundation Trust (appointed by BAPM's Executive Committee).

Professor James Boardman, Professor of Neonatal Medicine, University of Edinburgh.

Dr Daniel Connolly, Consultant Paediatric Neuroradiologist, Sheffield Children's Hospital NHS Foundation Trust.

Kate Dinwiddy, Chief Executive, BAPM.

Dr Anthony Hart, Consultant Paediatric Neurologist, Sheffield Children's Hospital NHS Foundation Trust.

Professor Axel Heep, Consultant Neonatologist, North Bristol NHS Trust.

Dr Sundeep Harigopal, Consultant in Neonatal Medicine, Newcastle Upon Tyne NHS Foundation Trust.

Dr Harriet Joy, Consultant Neuroradiologist, University Hospital Southampton NHS Foundation Trust.

Professor Karen Luyt, Professor of Neonatal Medicine, University of Bristol.

Dr Christina Malamateniou, Director of postgraduate programme in radiography, City, University of London.

Dr Nazakat Merchant, Consultant Neonatologist, West Hertfordshire NHS Trust.

Dr Chrysoula Rizava, Academic Clinical Fellow, Paediatric Specialty Trainee ST4, Sheffield Teaching Hospitals NHS Foundation Trust.

Professor Mary Rutherford, Professor of Perinatal Imaging & Health, King's College London.

Kelly Spike, Neonatal Critical Care Nurse, Cambridge University Hospitals NHS Foundation Trust.

Professor Brigitte Vollmer, Clinical and Experimental Sciences, Faculty of Medicine, University of Southampton; Neonatal and Paediatric Neurology, Southampton Children's Hospital, University Hospital Southampton NHS Foundation Trust.

List of abbreviations

ABE	Acute Bilirubin Encephalopathy
CHD	Congenital Heart Disease
CNS	Central Nervous System
cPVL	Cystic Periventricular Leukomalacia
CrUS	Cranial Ultrasound
CSVt	Central Venous Sinus Thrombosis
CT	Computerised Tomography
CVST	Cerebral Venous Sinus Thrombosis
DICOM	Digital Imaging and Communications in Medicine
DWI	Diffusion Weighted Imaging
ECMO	Extracorporeal Membrane Oxygenation
ELSO	Extracorporeal Life Support Organisation
EMR	Electronic Medical Records
ENS	Early Notifications Scheme
FLAIR	Fluid-attenuated Inversion Recovery
FSE	Fast Spin Echo
GA	Gestational Age
GMH	Germinal Matrix Haemorrhage
HIE	Hypoxic Ischaemic Encephalopathy
HPI	Haemorrhagic Parenchymal Infarction
ICH	Intracranial Haemorrhage
IVH	Intraventricular Haemorrhage
MDT	Multidisciplinary team
MRA	Magnetic Resonance Angiography
MRI	Magnetic Resonance Imaging
MRS	Magnetic Resonance Spectroscopy
MRV	Magnetic Resonance Venography
NE	Neonatal Encephalopathy
NICU	Neonatal Intensive Care Unit
NIHR	National Institute for Health and Care Research
PACS	Picture Archiving and Communication Systems
PAIS	Perinatal Arterial Ischaemic Stroke
PHVD	Post Haemorrhagic Ventricular Dilatation
PLIC	Posterior Limb of the Internal Capsule
PMA	Post Menstrual Age
PD	Proton Density
RCT	Randomised Controlled Trial
SWI	Susceptibility Weighted Imaging
TE	Echo Time
TEA	Term Equivalent Age
TH	Therapeutic Hypothermia
TIR	True Inversion Recovery
TOF	Time of Flight
TR	Repetition Time
WMI	White Matter Injury

Terms of reference, audit standards and early notification scheme

Magnetic resonance imaging (MRI) has become increasingly available to clinicians to evaluate the newborn. However, with the exception of MRI in term infants with hypoxic-ischaemic encephalopathy (HIE), there are no formal guidelines that address the clinical indications for and the practical aspects of MRI of the brain in this patient group within the NHS.

Terms of reference

The purpose of this document is to:

- Provide recommendations on clinical indications for and timing of neonatal brain MRI.
- To promote best practices for acquiring and reporting neonatal brain MR images.

The roles of MRI in post-mortem examination, fetal imaging and perinatal research are beyond the scope of this document, as are detailed sequence parameter recommendations for image acquisition on specific scanners.

The recommendations for scanning in this document are based on the use of 1.0T and 3.0T scanners; while ultra-low field, low field and ultra-high field scanners are available, they are not currently in widespread clinical use.

Recommendations for best practice

MR scanning of the newborn should be undertaken in a facility with radiographers experienced in examining this patient group. Radiologists with subspecialty training in paediatric radiology and/or neuroradiology should report these images. A network or regional approach and MDT review can facilitate this.

Audit standards

- A.** Infants born at term (≥ 37 weeks gestational age – GA) with acquired brain injury, neonatal encephalopathy (NE), and/or seizures should undergo MRI, which is the imaging modality of choice. For prognostic and diagnostic purposes, the optimal timing for image acquisition in cases of HIE is between 4 and 14 days after birth. In newborn infants with NE and/or seizures in whom HIE is not suspected, MRI should not be delayed and should be undertaken as soon as is safe and practical to do so.
- B.** In term infants with severe jaundice and clinical signs of acute bilirubin encephalopathy, MRI should be undertaken as soon as is safe and practical to do so.
- C.** MRI should be undertaken as soon as it is safe and practical to do so in any neonate with abnormal neurological signs (seizures and/or reduced consciousness) and blood glucose < 2.5 mmol/l.
- D.** In infants with CHD, MRI should be undertaken as soon as is safe and practical to do so if there are abnormal neurological signs, unexplained dysmorphic features, known genetic anomalies associated with brain abnormalities, or evidence of parenchymal injury on CrUS.
- E.** In infants undergoing ECMO, MRI should be undertaken as soon as is safe and practical to do so if there are abnormal neurological signs or evidence of parenchymal injury on CrUS.
- F.** MRI of the preterm infant at TEA (40-44 weeks PMA) should be if there is evidence of parenchymal injury on CrUS (large IVH, HPI, cPVL, PHVD, or focal pathology, including

cerebellar lesions), abnormal neurological signs or to aid diagnosis.

- G. The radiologist's report of an MR scan should be available on the hospital PACS system within two working days of the scan (90% target). Double reporting of MR scans is desirable. If scans are reviewed at a local or regional MDT, this should happen within 2 weeks of the scan. Ideally long-term follow-up clinical data and imaging outcomes should be fed back to the MDT.

Early Notification Scheme

The Early Notification Scheme (ENS), operated by NHS Resolution, investigates where there is evidence of, or the potential for, hypoxic-ischaemic brain injury having occurred in the first week following delivery or unexpected NICU admission for acute encephalopathy. The clinical definition of brain injury used in these cases was amended in April 2021, placing emphasis on imaging findings: 'Babies who have an abnormal MRI scan where there is evidence of changes in relation to intrapartum HIE' ¹.

Acquisition of neonatal MRI brain scans

Background

There are challenges to performing and acquiring a good quality MRI brain scan in the neonatal period. In most units, the MR scanner is located a distance away from the NICU and may be in a different hospital. Appropriately experienced staff need to accompany the neonate to the MR scanner and monitor them during both transportation and scan acquisition. This may require referral to the regional neonatal transfer team. Many scans on non-ventilated neonates are undertaken with them swaddled and following a feed. However, it is often difficult to acquire a comprehensive high-quality image dataset with a 'feed and wrap' procedure alone, and sedation (e.g. with chloral hydrate) may be considered. Poor quality images prevent full clinical interpretation. All staff involved in a neonatal MRI examination should be aware of the risks within the MRI environment, including a strong magnetic field, and have received appropriate MR safety training. Radiographers are responsible for data acquisition, patient care and MRI safety.

Preparing the neonate

Attention to preparation is essential to achieve a successful neonatal MRI brain examination. An MR safety questionnaire should be completed and signed by an individual with relevant MR safety training/accreditation. Equipment, sensors and implants are classified as MR safe, unsafe or conditional, and the MRI team must be informed before the baby arrives in the MRI facility if there are any positive answers to the safety questionnaire. The safety questionnaire should also be completed by staff accompanying the infant into the MRI facility. Awareness is needed that staff with implants may not be allowed into the MRI facility and so should not accompany the infant. While there is no contra-indication for pregnant staff to enter an MR facility, the MHRA advise that pregnant staff do not remain in the scan room whilst scanning is underway because of repeated exposure to acoustic noise and potential effects on the fetus. It is possible to scan ventilated neonates and or those on IV therapy as long as MR-safe or MR-conditional equipment is used.

Preparation for all neonates includes consideration about the volume and frequency of oral feeds. Swaddling the neonate will minimise movement during the scan. Ear protection will be required to reduce the noise at the eardrum to below 85dB(A) for both newborn infant and staff staying with the baby. Ear protection will also help the baby sleep during the scan. Reducing other environmental stimuli, such as dimming lights, may help induce sleep. A temperature check should be performed before and after the examination. MR-safe or conditional continuous temperature monitoring should be used if scanning a preterm infant. *Prior to taking the baby into the scanner room, a final safety review should be undertaken: 'pause and check'.*

If sedation is used, appropriate care pathways must be developed with neonatal and/or anaesthetic staff to ensure appropriate continuous monitoring of vital signs (i.e. heart rate, oxygen saturation levels) using MR-safe or MR-conditional equipment. Appropriate escalation pathways should exist in the event of a deterioration. Sedation should be tailored to the neonate's neurological state and the presence of additional sedatives or anticonvulsants. Sedation may be best given in the MRI department and close communication between neonatal staff and radiography staff is required to ensure minimal time is lost between sedation, the neonate falling asleep, and the scanner being available and prepared for a neonatal examination. Once sedated, the neonate be accompanied at all times by a staff member trained in neonatal resuscitation until they wake after the scan. If contrast is required, intravenous access should be secured before going into the scanner.

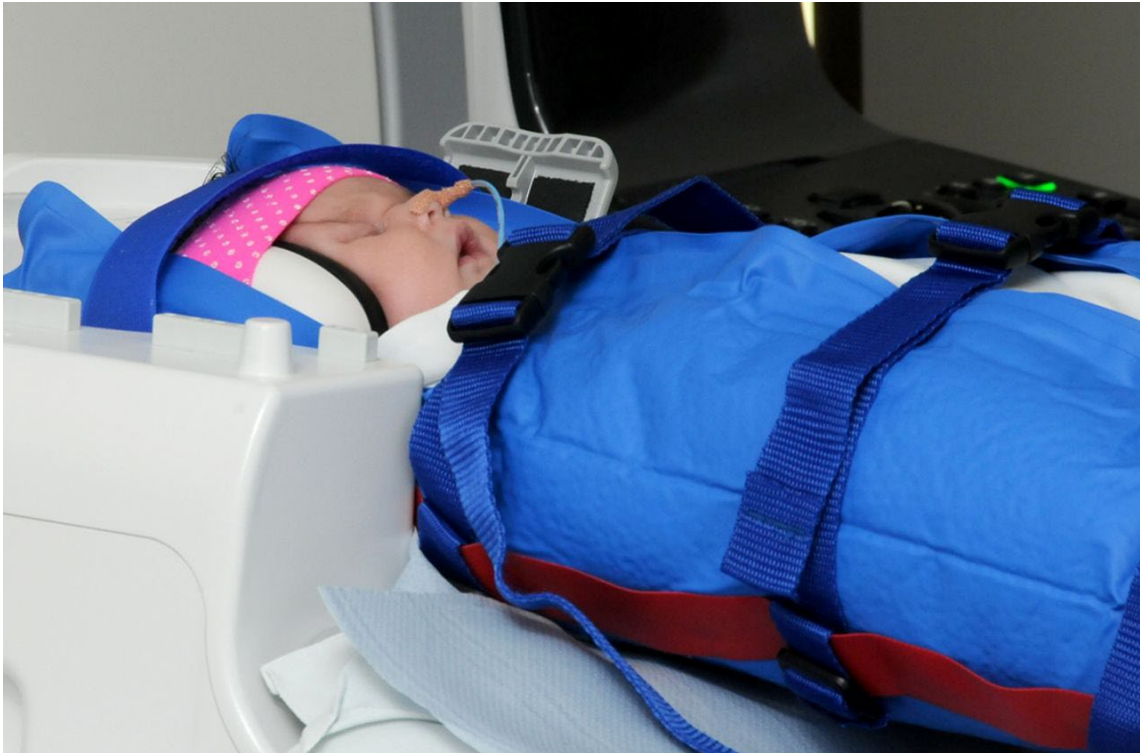

Figure 1 MRI of newborn infant. The neonate is swaddled with a Med-Vac immobiliser with appropriate ear protection ².

Timing of the scan

The timing of a neonatal MR brain scan depends on the gestational age of the infant and the clinical question being addressed (*see individual sections in the document*).

Scan protocol

The imaging protocol used needs to be suitable to detect a variety of conditions and tailored to the specific clinical history of the patient. The most effective approach is to have one comprehensive protocol as a neonatal exam card on the scanner with on table review of the imaging by a radiologist who can assess whether to either add extra MR sequences or remove unnecessary ones. Image signal-to-noise ratio is governed by the proximity of the coil to the neonatal head. Ideally, as small a coil as possible should be used; the head needs to be positioned in the centre of the bore to avoid signal intensity heterogeneity and minimise signal dropout.

Core Protocol

- Diffusion-weighted imaging (DWI) will detect acute infarction within hours of the injury and before it becomes visible T1- and T2-weighted images; but is useful at any time point to help time an injury. An ADC map should be produced.
- T1- and T2-weighted images, preferably in all three orthogonal planes, allow assessment of anatomy and definition of the exact site and extent of any acquired injury.
- Volumetric acquisitions may be used to avoid three separate planar acquisitions.
- Susceptibility weighted imaging (SWI) or gradient echo T2-weighted imaging allows better detection of haemorrhage and or calcium.

Sequences to be considered

- An MR venogram (MRV) may be added to the protocol if there is concern of cerebral venous sinus thrombosis (CVST) with or without associated parenchymal or intraventricular haemorrhage. MRV must be interpreted with caution in neonates due to the slow flow rate within veins, and specific sequences should be adopted.
- An MR angiogram (MRA) to confirm normal arteries, particularly in the presence of perinatal arterial ischaemic stroke (PAIS) is important and should include the neck vessels and the Circle of Willis.
- MRV and MRA may be acquired separately or as a combined time of flight (TOF) sequence.
- Proton (¹H) MR spectroscopy (MRS) is reported to be an accurate predictor of outcome in babies with HIE who have undergone TH ³⁻⁵. MRS can also be a valuable diagnostic adjunct in neonates with suspected metabolic encephalopathy.
- The acquisition and analysis of all imaging in this age group requires appropriately skilled and experienced staff but is of particular importance for MRS, when support from a physicist may be needed. Comparative normative data is required to allow accurate analysis. The use of MRS will depend on local expertise for acquisition and interpretation of results.
- If MRS is undertaken, the voxel should be placed over the left basal ganglia and thalami. An additional voxel may be placed over cerebral white matter if there is suspicion of a metabolic disorder.
- Volumetric T2-weighted imaging may be useful to assess the cerebral aqueduct if there is ventricular enlargement, or the inner ear structures in babies who have failed hearing assessment.

Optional sequences

- Proton Density (PD) weighted images can help with assessment of deep grey nuclei in HIE.
- FLAIR imaging may not add significantly to the neonatal sequences already mentioned.

As the neonatal brain has a higher water content than is found at later ages, T1 and T2 values are higher. The sequence parameters must be adjusted to account for this and provide the best tissue contrast. A core protocol is suggested in **Appendix 1**; all scan parameters are a starting point for image acquisition and require optimisation for individual MR scanners.

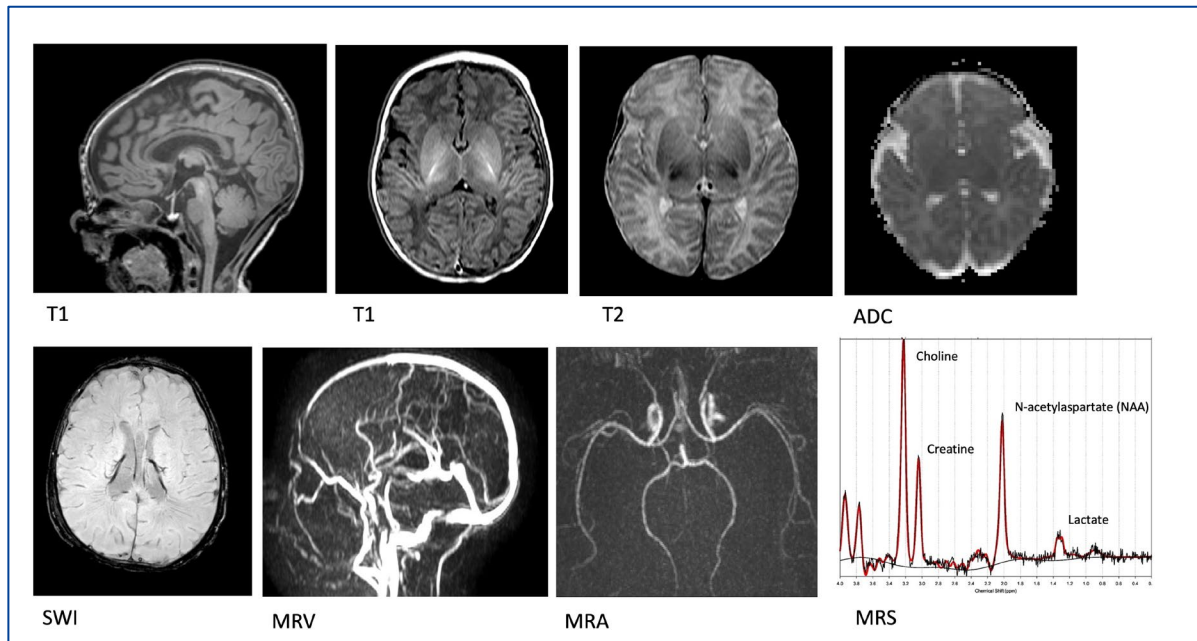


Figure 2 Normal appearances of the term neonatal brain. Top row, from left to right: T1-weighted (sagittal) T1-weighted (transverse), T2-weighted, diffusion weighted ADC map; bottom row, from left to right: susceptibility weighted image, magnetic resonance venogram, magnetic resonance angiogram, proton-magnetic resonance spectroscopy. Myelination can be seen as high signal intensity on T1- and low signal intensity on T2-weighted images. (Images courtesy of Professor Mary Rutherford).

Summary

- Acquiring a good quality brain scan is essential for accurate interpretation.
- Adequate time, training and resources should be available to ensure the infant is settled prior to and during the scan.
- The imaging protocol used needs to be optimised for the neonatal brain, suitable to detect a variety of conditions and tailored to the specific clinical history of the patient. To this end, a standard protocol for all babies may be useful.
- Communication, either formally through an MDT or informally between clinical teams (neonatologists, paediatric neurologists, neuroradiologists and radiographers) is important to ensure the scans are undertaken at a suitable time and with the appropriate sequences.
- Everyone involved in a neonatal MRI examination should know the risks within the MRI environment, including a strong magnetic field, and have received appropriate MR safety training.

Reporting of neonatal MRI brain scans

Background

The acquisition and interpretation of neonatal brain MRI is challenging compared with older patient groups because during the perinatal period:

- Appearances of the brain and regional structures differ from the adult brain and change with gestational age and postnatal maturation.
- Abnormalities may relate to specific perinatal pathologies not seen in adult neuroradiology.
- Acquired injuries evolve rapidly from the time of onset.
- Image quality may be suboptimal and movement artefacts are common.
- Tissue contrast changes rapidly due to evolving myelination, decreases in brain water content, and increases in tissue density.
- Contrast-to-noise ratio between grey and white matter may be lower if sequences are not well optimised for the neonatal brain.

Although all radiology trainees will encounter neonatal brain MRI scans during training, obtaining radiology CCT with subspecialist training in paediatric imaging and neuroradiology will provide greater experience in reporting images from this age group. All radiologists undergo annual appraisal and revalidation, which should include review of neonatal brain MR reporting if this forms part of their job plan. Double reporting of these studies is optimal, and at least one radiologist, preferably both, should have a subspeciality interest in paediatric brain MRI reporting. This may require the implementation of local reporting networks to ensure high-quality and timely reporting.

What the reporter wants to know

To provide a knowledgeable and reasoned assessment of an MRI scan, it is important to correlate the imaging with the clinical history and current clinical status of the baby⁶. Essential information which should be provided in the scan request is given in **table 1**; it should include key demographic and clinical information and a differential diagnosis. If other antenatal or postnatal imaging has been performed, then the reporting radiologists should be informed so that this imaging can be considered at the time of reporting the neonatal brain MRI. With increasing numbers of advanced neonatal practitioners in the workforce, Trusts should facilitate training to enable requests for MRI scans from non-medical professionals.

Table 1: Essential information that should be provided in the scan request.

Antenatal	Perinatal	Postnatal
Estimated date of delivery	Date & time of birth	Neurological signs and evolution Dysmorphic features
Maternal health (e.g. diabetes, drug use etc).	Gestational age at birth	Details of therapeutic cooling
Relevant obstetric/family history	CTG abnormalities	Information on hypotension, sepsis, hypoglycaemia, electrolyte disturbance
Abnormal findings on antenatal scans	Mode of delivery	Seizure activity history with aEEG and EEG findings, where available
	Presence of meconium	Evidence of organ dysfunction (heart/liver/kidney)
	Apgar scores at 1, 5, and 10 minutes	Clotting problems/thrombocytopenia
	Cord blood gases	Information on ability to feed orally
	Need for prolonged resuscitation	CrUS findings
	Birth weight, OFC	

What the referrer wants to know

The referrer requires a detailed review of the images, with particular detail of features that may be of diagnostic and prognostic value (e.g. the location of acquired parenchymal lesions – in particular, the appearances of the posterior limb of the internal capsule and deep grey nuclei, features consistent with a specific CNS malformation, congenital infection, or neurometabolic disorder, or specific patterns of injury that are associated with adverse outcome). Clinically important negative findings should be included. It is helpful to know whether further or repeat imaging is recommended.

A graded injury reporting system is rarely used outside of research settings and may be difficult to interpret for clinical purposes, but it may be agreed to be implemented locally. The use, or not, of specific reporting proforma should be agreed locally and would need to be compatible with local EMR systems. An example of a reporting proforma is given in Appendix 2.

If there are specific issues relating to the infant being scanned, it is always helpful to have a personal conversation between the radiology and clinical teams before the scan.

Reporting

The radiologist needs to be knowledgeable about the normal appearances of the neonatal brain across gestational ages 22-44 weeks and the range of potential pathologies evident on imaging for this population group. Images should be viewed and reported on high-quality imaging PACS monitors. The images should be available in a format which allows the radiologist to interrogate the imaging data fully. For instance, diffusion-weighted imaging should include the formation of an ADC map. MRV and MRA imaging should be available as DICOM data to allow multiplanar and 3D reformatting. MRS should be provided in a format that allows consistent reporting against normative

data. A formal written report should be available on the referring hospital PACS and patient information systems within two working days but preferably should be available the same day if it could inform clinical management.

It may be possible for an MRI scan to be performed in a local centre but there may not be a person with appropriate expertise available to report the images. Arrangements may be made for tertiary reporting of scans; in this situation, it is appropriate for the tertiary/reporting centre to advise on technical aspects of image acquisition detailing the sequences to be obtained. Regular audits on image quality may be useful.

In centres where reporting of neonatal MRI scans is undertaken but the number of cases is small (e.g. less than 12/year), review of scans by more than one radiologist with the provision of a consensus report is recommended. The second radiologist may be based at a larger centre and have greater experience of reporting neonatal brain MRI. A number of studies have shown improved reporting rates for various imaging investigations with the introduction of a second reader, and double reporting also serves to increase the experience of those involved ⁷.

Multidisciplinary teams and networks

Secondary review of neonatal brain MRI scans is advocated within the setting of an MDT, which may be convened at local, network or regional level depending on available expertise. MDT review is advised because coordinated expert review has the potential:

- To improve communication between the professionals involved and consequently result in more appropriate and consistent information being offered to parents.
- To share knowledge, expertise, and experience among a range of professionals and therefore serve as a platform for training and to reduce variation in the service provided nationally.

Whether performed and reviewed locally or performed locally with tertiary review of the imaging, there needs to be a clear process for communication between clinician and radiologist so that an appropriate clinically based opinion of the imaging can be given.

Levels of certainty of a diagnosis

The level of certainty of a diagnosis made on an MRI scan will be affected by the quality of the scan obtained as well as the experience of the reporting radiologist; movement artefact, in particular, can affect neonatal MRI scans, although this is minimised if careful, appropriate sedation or post-acquisition motion correction is used. Abnormalities detected are often subtle, making it more challenging to be sure they are present. The level of certainty of any finding on a scan needs to be conveyed adequately by the radiologist to the clinician because it may contribute to the decision-making process regarding further management.

Communication with parents

Parents or next of kin should be informed about the indication for an MRI scan, the timing of the scan, the process of undertaking the MRI scan in a neonate, and the process of reporting the scan. Parents will often place a lot of emphasis on the MRI scan being able to provide both an accurate diagnosis and detailed long-term outcome predictions. It is important to counsel parents as to the

value and limitations of MR scanning and that it is usually one several investigations, alongside the clinical history and examination which, when considered together, provides a full account of their baby's condition. Parents should be able to accompany their baby to the scanning department. They should also be told that once the scan is done, a report will not be available immediately.

Communication of the MRI report to the parents by the clinical team should be done promptly, preferably with both parents together and following any relevant discussion with radiologists and/or paediatric neurologists. Where possible, the imaging findings should be communicated by a member of the clinical team who is already known to the parents and has been involved in the baby's care. If the results and interpretation of the MRI scan are available at the time of transfer back to the local unit, arrangements should be made to communicate this information to parents and referral teams in a timely manner. Parents should be informed about the possibility of incidental findings being detected.

All discussions with parents must be clearly documented in the medical records.

Summary

- Neonatal MRI brain scans should be reported by appropriately trained and qualified radiologists, and the report and images saved to the hospital PACS system.
- Depending on caseload, review of scans by more than one reporter is advocated, either through double reading/reporting of the scan or within the setting of MDT/clinical-radiological meetings. MDT meeting outcomes should be documented and supplied to the clinical teams.
- Where possible, the development of regional networks is recommended to share experience.
- The person requesting the scan should be aware of the limitations of the neonatal MRI scan, and the parents should be counselled accordingly.
- Parents should be informed of the results of the scan promptly, following relevant discussion with neuroradiologists and/or paediatric neurologists. Results are best communicated by a member of the clinical team who is already known to the parents and has been involved in the care of their newborn infant.
- Parents should be counselled about the possibility of incidental findings, and services should have clinical pathways to manage actionable findings e.g. multidisciplinary review and/or a follow-up scan.

Term and near-term infants with neonatal encephalopathy & seizures

Background

Neonatal encephalopathy (NE) is a clinically defined syndrome of altered neurological function, characterised by difficulties establishing respiration, depression of tone and reflexes and alteration of consciousness. Seizures may or may not be a feature of NE, and not all infants with seizures are encephalopathic. Multiple aetiologies must be considered, and not surprisingly, there is considerable overlap in the differential diagnosis of a neonate presenting with encephalopathy and a neonate presenting with seizures.

The most common cause of NE and seizures is hypoxic-ischaemic encephalopathy (HIE). The diagnosis of HIE may not be apparent at presentation, and an open mind should be kept as to the aetiology or potential combination of aetiologies of encephalopathy and/or seizures in the neonate. This is particularly the case where the clinical course is atypical for HIE.

Apart from HIE, the differential diagnosis of NE and seizures includes focal cerebral injury (PAIS, CVST, primary intracranial haemorrhage), birth trauma, transient metabolic disturbances (hypoglycaemia, hypomagnesaemia, hyponatraemia), acute infections, drug exposure, inborn errors of metabolism, congenital brain malformations, tumours, neuromuscular disorders, neonatal-onset epilepsy syndromes and vitamin-responsive epilepsies.

Neuroimaging in neonates with encephalopathy and/or seizures

Neuroimaging is important for determining the aetiology of both NE and neonatal seizures, guiding clinical decision-making and prognosis, especially after hypoxic-ischaemic injury⁸ and informing risk management and medico-legal proceedings. Hypoxia-ischaemia is associated with well-described patterns of injury, which vary depending on a number of clinical factors including gestational age, and the nature, severity and timing of the insult. Neuroimaging also has a high diagnostic yield for other causes of NE and seizures with CrUS, MRI and occasionally CT scanning (e.g. if acute neurosurgical intervention might be needed and MRI isn't available) all having a role in the early management of these infants.

It is beyond the scope of this framework to describe specific injury patterns associated with NE and seizures, which are well described in the literature⁹, but it will instead focus on the image acquisition and timing of brain imaging following clinical presentation.

Cranial Ultrasound

All newborn infants presenting with NE and seizures should have a CrUS performed within 12 hours of admission because it can be helpful in detecting intracranial haemorrhage, antenatal brain injury and congenital brain lesions. Other lesions, such as focal arterial infarction, may not always be easily visualised at an early stage with cranial ultrasound.

Magnetic Resonance Imaging

MRI is warranted in all neonates with NE and/or seizures, even if the CrUS shows no obvious abnormality. Apart from infants with suspected HIE (the majority of whom with moderate-severe HIE having undergone TH), the ***MRI should not be delayed and should be undertaken as soon as it is safe and practical to do so*** after presentation.

Computed Tomography

There is growing evidence of potential long-term harm of CT scanning in infancy¹⁰. Early (non-contrast) CT should be limited to emergency situations when there is evidence of birth trauma and urgent imaging is required because acute neurosurgical intervention is being considered. In all other situations MRI is the imaging modality of choice. Rarely, CT may provide complementary information to MRI¹¹.

Diagnostic imaging in HIE

Perinatal asphyxia severe enough to cause HIE is the most common cause of NE and seizures in term and near-term infants. Therapeutic hypothermia (TH) for 72 hours after birth is the standard of care for all infants with moderate-severe HIE¹². MRI is the central component in both diagnosing the nature and extent of injury in HIE, as well as providing important prognostic information. Whilst MRI should not be delayed in other causes of NE and / or seizures, in neonates with HIE who may also be being cooled, it is particularly important to understand the temporal evolution of typical patterns of injury on the different MRI sequences. While DWI and T2-weighted sequences optimally detect injury on imaging before day 7 (and ideally before day 5), changes on T1-weighted sequences may not be as apparent until after day 5, with maximal injury evident at 10 to 14 days post injury. T1-weighted images are essential in the evaluation of myelin development alongside the findings from T2-weighted images. A comprehensive protocol with all recommended sequences should be used regardless of the timing of the scan. Cooling does not appear to change the pattern of injury on MRI if present¹³.

Timing of imaging in HIE

There has been considerable debate as to the merits of early (<6 days) versus late (>6 days) imaging, however, studies comparing early (~4days) to late (>7 days) have shown strong agreement⁹ and so timing should depend on local practicalities of obtaining a scan, as well as the clinical condition and stability of the infant. Moving a critically ill, ventilated infant on multiple inotropes to an MRI scanner is not without risk, and it may be worth waiting a few days until the infant is more stable; likewise, there is no reason to delay scanning an infant requiring minimal respiratory support once the baby has been rewarmed. Therefore, the recommendation is to scan the baby once rewarmed (i.e. from day 4), assuming the infant is clinically stable to be moved to the MRI scanner, and preferably no later than day 14. Good quality imaging acquired at a later time point whilst less optimal can still provide clinically valuable information.

In late preterm infants (<37 weeks' gestation) with HIE who have undergone TH, early MRI can be undertaken as described above; however, accurate assessment of myelination from the posterior limb of the internal capsule (PLIC) may require repeat imaging at term-equivalent age.

While there is some data to show that very early scanning during therapeutic hypothermia (2-3 days after birth) can be obtained safely, practical considerations should be taken for moving a baby being cooled in terms of maintenance of temperature, particularly given the heating effect of MRI on the infant. In a small number of infants with severe HIE, early MRI (i.e. within the first 72 hours) may be clinically indicated, particularly where redirection of intensive care is being considered. However, the reorientation towards palliative care should not be delayed while MRI is sought if criteria for discontinuing intensive care, as described in RCPCH and GMC guidance, are met. In some centres, post-mortem MRI may be used to complement conventional autopsy. However, the use of MRI in post-mortem examination is beyond the scope of this framework.

Repeat imaging (beyond one month of age) rarely provides any additional information on the nature

and extent of injury. Repeat imaging is usually only necessary if initial imaging has been of poor quality, certain important sequences were omitted, e.g. MRV or MRA, or there are unexplained new or persisting neurological symptoms in the infant not explained by the original images.

Prognostic utility of MRI/MRS in HIE

MRI is an important prognostic biomarker^{5 14-18}. When assigning prognosis, it is important to take into account the clinical history and neurological examination and results from other investigations including neurophysiological assessment. While it is beyond the scope of this framework to provide a comprehensive systematic review of all relevant MRI/MRS studies and long-term neurodevelopmental outcome, **table 2** summarises the accuracy of MR biomarkers in neonates with NE as predictors of the combined outcome of death and neurodevelopmental disability at 18-30 months of age. In the absence of MRI abnormalities, the likelihood of severe neurodevelopmental impairment is low.

In research settings, 1H-MRS is reported to be an accurate predictor of outcome in neonates with HIE who have undergone TH. Not all centres perform this routinely as it requires support from appropriately skilled and experienced staff, but where there is local expertise for acquisition and interpretation, it may contribute to prognostication.

Scoring System/ Abnormality	Biomarker cutoff	Design	Ref	Therapy	AUROC (95% CI)	Sensitivity	Specificity	PPV	NPV
Barkovich (BGT/WS score)									
Any MRI abnormality	BGT or WS ≥ 1	Prospective, observational	[131]	No TH	0.63 (0.57–0.68)	0.92	0.33	0.44	0.88
				TH	0.68 (0.56–0.81)	0.73	0.63	0.19	0.95
BGT	BGT \geq WS			No TH		0.87	0.70	0.68	0.88
				TH		0.69	0.88	0.45	0.95
Watershed	WS > BGT			No TH		0.83	0.39	0.30	0.88
				TH		0.33	0.69	0.05	0.95
Rutherford									
PLIC	PLIC equivocal or abn.	Prospective, observational	[42]	No TH		0.9	1.0	1.0	0.87
Any mod or severe abnormal.	BGT ≥ 2 ; WMI = 3 or PLIC	Prospective, RCT substudy	[94]	No TH	0.81 (0.71–0.91)	0.94	0.68	0.74	0.92
				TH	0.84 (0.74–0.94)	0.88	0.82	0.76	0.91
NICHD NRN	Any abn (MRI > 0)	Prospective RCT substudy	[95]	Mixed		0.90	0.65	0.62	0.91
Wash U	Total score > 10.5	Prospective, observational	[96]	TH	0.72 (0.57–0.86)	0.77	0.46	0.47	0.76
Weeke									
GM ^a + MRS	GM w/MRS ≥ 11.5	Retrospective, multicenter	[97]	TH (Cohort 1)	0.989 (0.973–1.0)	0.923	0.953	0.889	0.968
				TH (Cohort 1)	0.988 (0.973–1)	0.923	0.958	0.889	0.971
				TH (Cohort 2)	0.832 (0.708–0.955)	0.421	0.982	0.889	0.836
MARBLE									
BGT	BGT $\geq 1^b$	Prospective, multicenter, observational	[74]	TH	0.81 (0.75–0.87)	0.71	0.88	0.54	0.94
Cortex	WS $\geq 1^b$				0.67 (0.60–0.73)	0.48	0.81	0.33	0.89
PLIC	PLIC ≥ 1				0.82 (0.76–0.87)	0.71	0.90	0.58	0.94
Lac/NAA	Lac/NAA > 0.22				0.94 (0.89–0.97)	0.88	0.90	0.64	0.98
NAA	NAA ≤ 5.6 mmol/kg				0.99 (0.94–1.0)	1.0	0.97	0.86	1.0

Abbreviations: BGT, Basal Ganglia – Thalamus; GM, gray matter; MARBLE, Magnetic Resonance Biomarkers in Neonatal Encephalopathy; NAA, N-acetylaspartate; NICHD, National Institute of Child Health and Human Development; NRN, Neonatal Research Network; PLIC, posterior limb of the internal capsule; WS, watershed NAA, N-acetylaspartate.

Notes:

^a GM as defined in Weeke scoring system includes BGT, PLIC, brainstem, perirolandic and hippocampus.

^b MARBLE utilized the Rutherford scoring system above for characterizing BGT and cortical injury on MRI, but applied a different cutoff.

Table 2 The accuracy of MR biomarkers in neonates with neonatal encephalopathy (NE) as predictors of the combined outcome of death and neurodevelopmental disability at 18–30 months of age⁹.

Imaging term infants with mild HIE

There is some evidence that infants with mild HIE have increased neurological morbidity and that mild HIE can be associated with MRI abnormalities^{19 20}. However, there is no clear agreed definition of mild HIE and the predictive value of MRI on neurological outcomes in mild HIE is not known with certainty. It is important to consider these uncertainties carefully when undertaking a decision to scan and parents should be made aware of this and the challenges of interpreting abnormalities of unknown significance.

MRI, however, can be undertaken in this group of infants if there is uncertainty surrounding the diagnosis or if there are atypical neurological features.

Diagnostic imaging in focal infarction or haemorrhage with or without cerebral venous sinus thrombosis

Focal infarction resulting from perinatal arterial ischaemic stroke (PAIS) may present as isolated seizures in an otherwise well newborn infant within the first 48 hours after birth. It is more common in primigravida mothers, following instrumental delivery or where instrumental delivery failed and caesarean section was required, and in male neonates. The left middle cerebral artery is most commonly affected. Occasionally, it can present in an encephalopathic neonate, in a neonate with symptomatic hypoglycaemia or in an infant with meningitis.

Neonatal cerebral haemorrhage may be associated with cerebral sinus venous thrombosis (CVST), an acquired or congenital coagulation disorder, or it may complicate infection or, less commonly, a metabolic disorder. Occasionally, haemorrhage may relate to a vascular anomaly.

MRI is the most sensitive modality of choice, and imaging should be performed when safe and practical to do so. MRA of both the circle of Willis and the neck vessels and MRV may be particularly useful in informing aetiology. MRA and MRV sequences should be included if there is suspicion of infarction or thrombosis.

Summary Recommendations

- MRI is the imaging modality of choice for diagnostic imaging in NE and/or seizures.
- In newborn infants with NE and/or seizures in whom HIE is not suspected, ***MRI should not be delayed and should be undertaken as soon as it is safe and practical to do so.***
- MRI is useful in aiding diagnosis or cause of injury, timing of injury and prediction of neurological and developmental outcomes in newborns with hypoxic-ischaemic encephalopathy (HIE)
- In the case of newborn infants with NE and/or seizures, in whom there is a high suspicion of perinatal hypoxia-ischaemia, ***MRI should be undertaken between 4 and 14 days of life,*** taking care to interpret findings from the different sequences depending on the exact timing of the scan. If the infant is stable, early imaging (<6 days) can accurately identify injury, providing a complete and optimised good quality image dataset, including diffusion-weighted sequences, is acquired.

Antenatal abnormalities of the brain

Background

Brain abnormalities that predate delivery include both structural malformations and acquired injuries. The latter may have hypoxic, ischaemic, haemorrhagic or infectious aetiologies, isolated or combined. Structural abnormalities may be isolated or part of a syndrome and may or may not have a known genetic aetiology. Recently, rapid whole exome and genome analysis is increasing the diagnostic yield in fetuses with non-pathognomonic brain findings ²¹. In some neonates, there may be non-CNS abnormalities or dysmorphic features but no previously diagnosed brain abnormality. The most common antenatally diagnosed fetal brain anomaly is ventriculomegaly; this is often isolated, but MRI may detect additional abnormalities that influence both diagnosis and prognosis for the infant. The most frequently missed brain anomaly on antenatal US is agenesis of the corpus callosum ²².

Imaging

Antenatal MRI has superior diagnostic accuracy and confidence for fetal brain abnormalities compared to ultrasound ²³. However, it is still limited in terms of resolution and is prone to artefact from fetal motion unless motion correction approaches are employed. In addition, brain anomalies may become more overt with increasing gestation. Postnatal imaging in any baby with an antenatally diagnosed cerebral abnormality is recommended, and, in the majority, postnatal MRI will be warranted. A detailed review on the indication, practicalities and timing of antenatal MRI is beyond the scope of this framework.

Postnatal brain MRI can usually be performed when feasible within the first month of life, including as an outpatient following discharge home, to detect an undiagnosed developmental abnormality, confirm antenatal findings, better assess regional brain structures and maturity and exclude any additional acquired injury. Urgent brain MRI may be needed in neonates with evidence of suspected vascular anomaly such as a Vein of Galen malformation, obstructive ventricular dilation or those with a myelomeningocele.

A standard MR neonatal brain examination should be performed. Further sequences may augment the study if clinically indicated, for instance, a heavily T2-weighted sequence to assess CSF flow through the cerebral aqueduct in the assessment of neonates with ventricular dilation. In babies who have failed a hearing assessment, additional T2 volumetric MR imaging of the cochleas and internal auditory canals provides valuable information and can in critical therapeutic decision-making. Good quality MRI allows better definition of the brain phenotype which may assist in determining a specific diagnosis or in focusing further investigations to determine underlying aetiology. Whilst neurodevelopmental outcome may be dictated by the final diagnosis or the presence of additional clinical features, this may be further informed by MRI findings.

Summary Recommendations

Postnatal MRI may aid the diagnosis and identification of additional brain anomalies in neonates with suspected or confirmed antenatal brain abnormalities. The decision to scan an individual infant will depend on the results of antenatal investigations, the possible diagnosis, and the need for further prognostic information.

Congenital and acquired infection

Congenital infection

Congenital infections may be viral, bacterial or protozoan. An antenatal infection may be suspected following maternal clinical symptoms or fetal ultrasound findings and may be confirmed following maternal blood testing and amniocentesis. A congenital infection may not be considered until after delivery in a neonate with, for example, fetal growth restriction, skin rash, hepatosplenomegaly²⁴. The most common viral infection is cytomegalovirus occurring in 0.3-2.4% of live births; in mothers with a first infection during pregnancy, 30-40% of fetuses will become infected²⁵.

Infection may affect many body systems with well-documented patterns of injury in the fetal and neonatal brain^{26 27}. MR imaging will not provide information on any associated hearing loss. Less common but clinically significant viral infections that may infect the fetal CNS include parvovirus, rubella and varicella, which may all demonstrate characteristic findings on imaging²⁸. Toxoplasmosis may be clinically silent or produce symptoms during pregnancy. Diagnosis is difficult, but treatment may be started prior to delivery to prevent CNS and ocular injury in the baby. MR imaging is useful to exclude or assess the extent of CNS involvement, which may include parenchymal infarctions, calcification with ventricular dilation.

Fetal bacterial infections include *Listeria*, which may cause stillbirth, precipitate delivery and may result in significant brain injury. These sequelae may be avoided if there is a prompt maternal diagnosis and appropriate antibiotic treatment is commenced. Maternal chorioamnionitis from a variety of bacteria may have a detrimental but indirect effect on the fetal brain with conditions such as periventricular leukomalacia and diffuse white matter injury associated with the corresponding fetal immune response²⁹.

Imaging in congenital infection

Neonatal MRI may confirm fetal and/or neonatal CrUS findings or detect additional abnormalities such as abnormal white matter signal, focal infarctions or cysts and abnormalities in the cortex and cerebellum. CrUS may be better than MRI at detecting calcification, thalamo-striatopathy, and subependymal cysts. A routine MR protocol designed for brain injury is appropriate in the investigation of congenital infection and should therefore include T1-weighted and T2-weighted sequences, a GE sequence or SWI, and DWI. An MRI may be required urgently in a neonate with confirmed CMV infection as confirmation of brain involvement may be an indication for antiviral treatment.

Acquired infections

Acquired neonatal infections may be bacterial, viral or fungal, with characteristic patterns of brain injury from direct infection or indirect injury due to vasculitis, thrombosis or obstructive ventricular dilation. The most common neonatal bacterial CNS infection is Group B streptococcus. Neonatal infection may be early, with an incidence of 0.57/1000 live births or have late onset with an incidence 0.27/1000 live births, in the UK and Ireland. The incidence of meningitis is higher with late onset disease and carries a significant around an 8% risk of mortality and a 40% risk of morbidity. Other bacteria that are associated with neonatal CNS invasion and subsequent neurological sequelae include gram negative bacteria, *E. Coli*, *Klebsiella*, *Pseudomonas* and *Citrobacter* species.

The most common viral infections presenting with neurological injury in neonates are herpes simplex virus and the enteroviruses, e.g. echovirus and parechovirus. Once again MRI findings may be characteristic with several reports in the literature ²⁸.

Neonatal fungal infections are more common in the preterm population, particularly in neonates with necrotising enterocolitis, following abdominal surgery, prolonged ventilation, prolonged or repeated antibiotic therapy, or with candida colonisation. Typical candida micro abscesses may not be detectable with CrUS, and MRI is recommended if there is suspicion of CNS disease.

Imaging in acquired infection

MR imaging may be warranted in a neonate with a complicated bacterial or fungal acquired infection if they have been severely ill with superadded neurological signs or have an abnormality detected on CrUS. MR imaging may also be warranted in a neonate with acquired viral encephalitis. The standard neonatal brain examination should be acquired. A discussion about the merit of contrast should be had prior to preparing for MRI and IV access secured in preparation if indicated. Reasons for giving contrast include a suspected focal abscess, although an acute infarction may also enhance with contrast, and confirmation of meningeal involvement. MRA and MRV should also be considered because vasculopathy and CVST may complicate infection. Bacterial meningitis may be complicated by labyrinthitis ossificans. In babies who have failed hearing assessment, heavily T2-weighted MR imaging of the cochleae and internal auditory canals provides valuable information and aids in time-critical cochlear implant (prior to cochlear sclerosis).

Imaging can be performed once the baby is stable or more promptly to investigate a focal lesion detected on CrUS, ventricular dilation, or unexplained neurological signs.

Summary Recommendations

For congenital and acquired infection, imaging may be performed as soon as it is practical and safe to do so to complement antenatal investigations where obtained. Imaging for acquired infection is advised in the presence of neurological signs and/or an abnormality on CrUS. It may be obtained as soon as the neonate is stable. Contrast administration may be warranted if there are concerns about complications of bacterial meningitis. MRA and MRV should be considered to exclude potential vascular complications. In babies who have failed a hearing assessment, additional T2 volumetric MR imaging of the cochleae and internal auditory canals provides valuable information and can aid in time-critical therapeutic decision making.

Neonatal hyperbilirubinaemia

Background

Neonatal hyperbilirubinaemia can result in acute neurological dysfunction, known as acute bilirubin encephalopathy (ABE). Although ABE and kernicterus are used interchangeably, technically, kernicterus refers to the deposition of bilirubin in the globus pallidus, subthalamic nuclei and hippocampi. Bilirubin-induced neurological dysfunction (BIND) refers to longer term clinical sequelae resulting from kernicterus, which includes high-tone sensory hearing loss and dystonic cerebral palsy with or without cognitive impairments.

Causes include Rhesus or ABO incompatibility. Bilirubin levels at which injury may occur vary according to the gestational age of the infant and additional factors such as the presence of sepsis or metabolic acidosis and individual genetic susceptibility. There are currently guidelines for acting upon bilirubin levels with phototherapy or exchange transfusion³⁰. In addition to the presence of jaundice, symptoms of hyperbilirubinemia suggestive of ABE include poor feeding and neurological abnormalities of tone, with or without seizures. Jaundice in a term baby may not be as easily identified in infants with darker skins. Early neonatal discharge requires careful community follow-up to ensure early jaundice is not missed.

Imaging

MRI should be undertaken in a neonate with severe hyperbilirubinaemia and signs of ABE because CrUS is unable to detect lesions associated with kernicterus³¹. Imaging within the neonatal period may reveal abnormalities with high signal on T1-weighted images within the globus pallidus and subthalamic nuclei, but this is variable and may be difficult to distinguish from normal findings of high signal intensity in these regions. In addition, signal intensities on T2-weighted imaging are unremarkable in the neonatal period. If neonatal abnormalities are present, then there are usually long-term clinical sequelae. If neonatal imaging is unremarkable and there are ongoing clinical concerns, then repeating the MRI beyond six months of age may be informative. Later imaging shows a reversal of the abnormal signal intensities in the globus pallidus with characteristic low signal on T1-weighted and high signal on T2-weighted images. Hippocampal involvement and atrophy may also be detected. There are currently no imaging correlates for sensorineural hearing loss.

Summary Recommendations

An MRI scan should be undertaken in a neonate with severe hyperbilirubinaemia associated with ABE. A standard neonatal brain MRI protocol is appropriate and best done as soon as it is safe and practical. If neonatal imaging is considered normal, a repeat scan after six months of age may be useful in infants with ongoing neurological concerns. MRI cannot give information on the likelihood of hearing impairment.

Neonatal hypoglycaemia

Background

Hypoglycaemia is the most common metabolic problem in the neonatal period. It is unclear what the effect of mild transient, clinically asymptomatic hypoglycaemia is on brain development and neurodevelopment. However, there is strong evidence for a correlation between severe prolonged hypoglycaemia, brain injury, and neurodevelopmental impairment^{32 33}.

Term infants at risk of impaired metabolic adaptation are at higher risk of hypoglycaemia and adverse neurological sequelae. These include infants of diabetic mothers, infants whose mothers have taken beta-blockers, and infants with intrauterine growth restriction (IUGR). Hypoglycaemia may very rarely be a presenting sign in neonates with pituitary abnormalities.

The BAPM Framework for Practice on Neonatal Hypoglycaemia used the following definitions for hypoglycaemia³⁴:

- *Transient*: one measurement of 1.0-1.9mmol/L within the first 48 hours after birth in an infant with no abnormal signs who is feeding effectively.
- *Recurrent*: more than two measurements of 1.0-1.9mmol/L during the first 48 hours after birth.
- *Severe*: <1.0mmol/L on a single occasion.

The framework used an operational threshold of hypoglycaemia to guide interventions intended to raise blood glucose in the first 48 hours:

- A value <1.0mmol/l at any time.
- A single value <2.5mmol/l in a neonate with abnormal clinical signs.
- A value <2.0mmol/l and remaining <2.0mmol/l at the next measurement in a baby with a risk factor for impaired metabolic adaptation and hypoglycaemia but without abnormal clinical signs.

Neuroimaging in neonatal hypoglycaemia

Severe and recurrent or prolonged hypoglycaemia can cause brain injury; the greatest risk is in infants with accompanying signs of acute neurological dysfunction. The most frequent injury pattern seen on MRI is in the parieto-occipital white and grey matter regions, with white matter being predominantly affected; other regions which may be involved are periventricular white matter, the basal ganglia and thalami, and the corpus callosum. Focal infarcts may also be seen^{35 36}. MRI should be undertaken in any neonate with seizures and/or reduced consciousness (lethargy, stupor, or coma) and blood glucose <2.5mmol/l because of the risk of brain injury and neurodevelopmental impairment in this group. MRI is not required for transient low blood glucose without abnormal neurological signs, although if the transient low blood glucose was <1.0mmol/l and there is uncertainty about the documented presence/absence of acute neurological dysfunction, then clinicians should consider referral for MRI. A standard neonatal brain MRI protocol is appropriate and best done as soon as it is safe and practical to do so.

Summary Recommendations

While hypoglycaemia is associated with brain injury and neurodevelopmental impairment, the relationship between the severity and duration of hypoglycaemia and potential for injury is not straightforward. MRI should be undertaken in any neonate with seizures and/or reduced consciousness (lethargy, stupor or coma) and blood glucose $<2.5\text{mmol/l}$ because of the risk of brain injury and neurodevelopmental impairment in this group. MRI is not required for transient low blood glucose without abnormal neurological signs, although if the transient low blood glucose was $<1\text{mmol/l}$ and there is uncertainty about the documented presence/absence of acute neurological dysfunction, then clinicians should consider referral for MRI.

The pattern of injury acquired can aid prognosis for neurodevelopmental outcomes. However, a normal scan does not always exclude neurodevelopmental sequelae.

Term infants with congenital heart disease

Background

Survivors of CHD are at increased risk of a wide spectrum of neurodevelopmental impairment throughout childhood, including delayed motor milestones and slower cognitive and language development³⁷. Complex cognitive and motor dysfunction may only emerge as the child becomes older. In infants with complex CHD, up to 50% may have neurodevelopmental impairments³⁸. A significant number of infants with CHD have an underlying genetic disorder, which may also be associated with adverse neurodevelopmental sequelae³⁹. There is good evidence that delayed brain maturation begins in utero due to the aberrant fetal circulation leading to reduced oxygen and nutrient supply to the brain⁴⁰. Other factors associated with a worse outcome include preterm birth, long intensive care stay and ventilatory support, and infants from a poorer socioeconomic environment³⁷. Postnatally, infants are at risk of acquired brain injury which can occur both pre- and post-operatively.

Neuroimaging of the term infant with CHD

Infants with CHD are at increased risk of a wide spectrum of developmental and acquired cerebral lesions resulting in abnormal neurodevelopmental outcomes. Some infants will have underlying genetic conditions (e.g. 22q deletion, Trisomy 21) with overt structural anomalies and/or brain dysmaturation. Aberrant fetal circulation alone may impair brain development, and lesions may also be acquired peripartum or in association with surgical interventions. There is a wide spectrum of cerebral lesions reported in infants with CHD, with the most common findings being white matter injury, focal infarcts, haemorrhagic lesions and CVST⁴¹. Focal ischaemic lesions are more common following septostomy, but in general, cerebral injury and subsequent neurodevelopmental problems result from a combination of altered antenatal brain development and pre- and post-operative embolic and/ or hypoxic-ischaemic events⁴².

Two systematic reviews summarising the pre-operative neuroimaging findings in infants with CHD found a significant number of infants with developmental or acquired abnormalities on CrUS or MRI^{43 44}. The American Heart Association in 2012 recommended that all high-risk infants with CHD should undergo structured neurodevelopmental surveillance, and MRI should be undertaken if there are abnormal neurological signs or evidence of parenchymal brain injury or intracranial haemorrhage on CrUS³⁸. However, in view of the growing literature on pre- and post-operative imaging and neurodevelopmental outcome, MRI in the fetal and early neonatal periods may help in elucidating the timing of onset of altered brain development and acquired injury in infants with critical CHD (e.g. hypoplastic left heart syndrome (HLHS) pulmonary atresia with intact ventricular septum, simple transposition of the great arteries (TGA), interruption of the aortic arch and all infants requiring surgery within the first 28 days of life with the following conditions: coarctation of the aorta (CoA); aortic valve stenosis; pulmonary valve stenosis; tetralogy of Fallot (TOF); pulmonary atresia with ventricular septal defect (VSD); total anomalous pulmonary venous connection).

Summary Recommendations

In infants with CHD pre- and post-operative MRI may help in defining the timing and extent of cerebral injury and should be considered in infants with critical CHD. MRI should be undertaken in all infants where there are abnormal neurological signs, unexplained dysmorphic features, known genetic anomalies associated with brain abnormalities, or evidence of parenchymal injury on CrUS.

Term infants requiring extracorporeal membrane oxygenation

Background

Extracorporeal membrane oxygenation (ECMO) is a modified form of cardiopulmonary bypass that provides cardio-respiratory support in severe respiratory or cardio-respiratory failure. It is effective at reducing mortality and morbidity in eligible neonates ⁴⁵. Neurological complications are relatively common in infants supported with ECMO ⁴⁶. Intracranial injury can occur in neonates because of illness severity prior to treatment (including prolonged periods of hypoxia, hypocarbia, cardiovascular instability, acidosis, and altered cerebral autoregulation) and/or ECMO-related phenomena (including complications associated with cannulation of central arterial/venous vessels, diminished pulsatility in veno-arterial (VA) ECMO, use of anticoagulants, and microthrombi from the circuit). Long-term neurodevelopmental impairment ranges from 15% to 50% in these infants. Those at higher risk for neurological complications include infants with a diagnosis of congenital diaphragmatic hernia, preterm infants, infants less than 3kg, VA ECMO, longer duration of ECMO, pre-ECMO lactate and pre-ECMO cardiac arrest ⁴⁷⁻⁵¹.

Neuroimaging of the term infant on ECMO

The most common types of brain injury associated with ECMO are ischaemic or haemorrhagic lesions, but generalised atrophy or ventricular dilatation has also been reported ⁵²⁻⁵⁶. Current guidelines from the Extracorporeal Life Support Organisation (ELSO) recommend CrUS before initiation of ECMO support and daily for the first 3-5 days after cannulation. While CrUS is good at identifying major ICH it is less sensitive for small ICH or ischaemic lesions. ELSO recommends neonates undergo advanced imaging after completion of ECMO therapy and prior to hospital discharge, with studies showing that CrUS significantly underestimates cerebral lesions ⁵¹. However, there is a paucity of evidence correlating early imaging with clinical outcomes. This may reflect the relative infrequency of ECMO and a lack of large multicentre studies. Routine MRI following ECMO would be best undertaken in the context of a research study or registry data collection alongside longer-term neurodevelopmental follow-up. In infants in whom there are abnormal neurological signs or evidence of parenchymal brain injury on CrUS, MRI is recommended following completion of ECMO.

Summary Recommendations

Infants undergoing ECMO are at risk of intracranial injury due to both the underlying pathology and complications of ECMO itself. Serial CrUS before and during ECMO is recommended but it may underestimate the degree of cerebral injury. There is only a limited amount of data relating acute brain injury following ECMO with long term neurodevelopmental problems. MRI following ECMO is recommended in infants in whom there are abnormal neurological signs or evidence of parenchymal brain injury on CrUS.

Preterm infants

Background

Preterm birth (<37 weeks GA) is a leading cause of neurodevelopmental impairment in childhood. The most common injuries are intraventricular haemorrhage (IVH), haemorrhagic parenchymal infarction (HPI) and white matter injury (WMI). The preterm infant is particularly susceptible to haemorrhagic brain injury that is apparent in CrUS in the first few days of life. Injury or dysmaturation from ischaemic and or inflammatory processes that is visible on neuroimaging usually evolves over several weeks after very preterm birth. The aetiology is complex and multifactorial and is associated with long-term neurodevelopmental impairment. The BAPM Framework on the perinatal management of extreme preterm birth before 27 weeks of gestation define severe impairment as including any of:

- Severe cognitive impairment with an IQ lower than 55 (<-3 standard deviations); this will usually result in the need for educational support and require supervision in daily activities.
- Severe cerebral palsy – classified as Gross Motor Function Classification System (GMFCS) grade 3 or greater.
- Blindness or profound hearing impairment

The risk of severe impairment resulting from preterm birth increases with decreasing gestation. For infants born alive who receive active treatment, at 22 weeks of gestation the risk for severe impairment is 24-43%, while at 26 weeks, the risk drops to 6-14%⁵⁷.

Neuroimaging of the preterm infant

Sequential CrUS is the standard imaging modality and will reliably detect germinal matrix haemorrhage (GMH), IVH, cPVL, PHVD⁵⁸⁻⁶².

MRI at TEA (40-44 weeks GA) provides more anatomic detail than CrUS, which has led to:

- A greater appreciation of the nature and extent of periventricular white matter abnormalities⁶³⁻⁶⁶.
- Detailed visualisation of the posterior limb of the internal capsule and cerebellar injury, both of which may carry prognostic significance^{67 68}.
- The appreciation of basal ganglia and thalamic injury.

However, there is debate about the value of an MRI at term equivalent age, particularly in an infant with no anomaly seen on CrUS. A recent meta-analysis of 11 studies comparing CrUS to brain MRI at TEA in detecting preterm brain injury showed significant heterogeneity in the studies⁶⁹. Three studies reported a third to a half of preterm infants with a normal CrUS had anomalies detected on brain MRI; however, they were mostly mild white matter abnormalities. Cerebellar haemorrhage is recognised in 3.7-9% of CrUS scans of preterm infants and around 19% of MRI scans, with smaller haemorrhages detectable on MRI only⁷⁰⁻⁷². The NIHR-funded ePRIME RCT (n=511 participants) with nested diagnostic and cost evaluations was carried out to inform NHS practice about the use of MRI in preterm infants⁷³. The study reported that, compared to ultrasound, MRI increased costs with only modest benefits to parental wellbeing and outcome prediction. So, MRI at term equivalent age is not indicated for all infants born at <33 weeks' gestation.

Prediction of neuromotor outcome

A CrUS with no major abnormality (defined absence of grade 3-4 IVH, cPVL or focal infarction) is highly predictive of survival without cerebral palsy (specificity 95%)⁶⁰. However, its sensitivity for cerebral palsy is low, with estimates ranging from 18% to 67%⁷⁴⁻⁷⁷. The ePrime RCT showed that MRI predicted moderate to severe functional motor impairment at 20 months only slightly better than CrUS: AUC 0.74 (CI 0.66-0.83) for MRI versus 0.64 (CI 0.56-0.72) for CrUS⁷³.

Prediction of cognitive outcome

The specificity of CrUS for predicting cognitive outcome is lower than it is for neuromotor outcome: the pooled probability of a normal cognitive outcome with a normal ultrasound scan is estimated to be 82% (95% CI 79-85)⁷⁸. The ePrime study reported that MRI has high specificity 88.9% (95% CI 85.2-91.9) but low sensitivity 27.9% (95%CI 19.8-37.2) for predicting scores <85 on the Bayley-III cognitive domain at 2 years of⁷³. The area under the receiver operator characteristic curve is <0.6 for both modalities. These findings are consistent with a low sensitivity of neonatal neuroimaging for predicting cognition at 5 years of age after very preterm birth⁷⁹.

11.5 Indication for MRI in preterm infants

MRI should be considered if there is evidence of parenchymal injury on CrUS (large IVH, HPI, cPVL, PHVD, or focal pathology, including cerebellar lesions), abnormal neurological signs, or to aid diagnosis.

Timing of MRI in preterm infants

If the clinical team decide MRI is indicated for the reasons given above, the optimal timing is 40-44 weeks because this allows for assessment of brain maturation and myelination. In some circumstances, an earlier MRI may be beneficial if neurometabolic disease, congenital infection or CNS malformation are suspected, to assist surgical planning (e.g. for PHVD treatment), in infants with unexplained abnormal signs, or to inform end-of-life decisions. If an earlier scan is being considered, then it must be undertaken in a centre equipped to care for preterm infants in the MRI environment.

Summary Recommendations

MRI is not routinely indicated for all preterm infants as available evidence indicates it only adds modest value to CrUS for predicting outcomes, which has to be balanced against the logistics and cost of scanning. MRI should be undertaken if there is evidence of parenchymal injury on CrUS (large IVH, HPI, cPVL, PHVD, or focal pathology, including cerebellar lesions), abnormal neurological signs, or to aid diagnosis. The optimal timing for MRI of the preterm infant is 40-44 weeks postmenstrual age because this allows for assessment of brain maturation and myelination. In some circumstances, an earlier MRI may be beneficial if neurometabolic disease, congenital infection or CNS malformation are suspected, to assist surgical planning (e.g. for PHVD treatment), in infants with unexplained abnormal signs, or to inform end-of-life decisions.

References

1. Resolution N. HSIB and NHS Resolution Early Notification Scheme update webinar [Available from: <https://resolution.nhs.uk/wp-content/uploads/2021/06/EN-and-HSIB-webinar-FAQs-.pdf>.
2. Ibrahim T, Few K, Greenwood R, et al. 'Feed and wrap' or sedate and immobilise for neonatal brain MRI? *Arch Dis Child Fetal Neonatal Ed* 2015;100(5):F465-6. doi: 10.1136/archdischild-2015-308847 [published Online First: 2015/07/02]
3. Lally PJ, Montaldo P, Oliveira V, et al. Magnetic resonance spectroscopy assessment of brain injury after moderate hypothermia in neonatal encephalopathy: a prospective multicentre cohort study. *Lancet Neurol* 2019;18(1):35-45. doi: 10.1016/S1474-4422(18)30325-9 [published Online First: 2018/11/19]
4. Lally PJ, Pauliah S, Montaldo P, et al. Magnetic Resonance Biomarkers in Neonatal Encephalopathy (MARBLE): a prospective multicountry study. *BMJ Open* 2015;5(9):e008912. doi: 10.1136/bmjopen-2015-008912 [published Online First: 2015/10/02]
5. Mitra S, Kendall GS, Bainbridge A, et al. Proton magnetic resonance spectroscopy lactate/N-acetylaspartate within 2 weeks of birth accurately predicts 2-year motor, cognitive and language outcomes in neonatal encephalopathy after therapeutic hypothermia. *Arch Dis Child Fetal Neonatal Ed* 2019;104(4):F424-F32. doi: 10.1136/archdischild-2018-315478 [published Online First: 2018/10/17]
6. The Royal College of Radiologists. Standards for interpretation and reporting of imaging investigations: Reference BFCR(18)1, 2018.
7. Goddard P, Leslie A, Jones A, et al. Error in radiology. *Br J Radiol* 2001;74(886):949-51. doi: 10.1259/bjr.74.886.740949 [published Online First: 2001/10/25]
8. Barkovich AJ. MR imaging of the neonatal brain. *Neuroimaging Clin N Am* 2006;16(1):117-35, viii-ix. doi: 10.1016/j.nic.2005.10.003 [published Online First: 2006/03/18]
9. Wisnowski JL, Wintermark P, Bonifacio SL, et al. Neuroimaging in the term newborn with neonatal encephalopathy. *Semin Fetal Neonatal Med* 2021;26(5):101304. doi: 10.1016/j.siny.2021.101304 [published Online First: 2021/11/06]
10. Mathews JD, Forsythe AV, Brady Z, et al. Cancer risk in 680,000 people exposed to computed tomography scans in childhood or adolescence: data linkage study of 11 million Australians. *BMJ* 2013;346:f2360. doi: 10.1136/bmj.f2360 [published Online First: 2013/05/23]
11. Sorokan ST, Jefferies AL, Miller SP. Imaging the term neonatal brain. *Paediatr Child Health* 2018;23(5):322-28. doi: 10.1093/pch/pxx161 [published Online First: 2019/01/19]
12. Medicine BBAoP. Therapeutic Hypothermia for Neonatal Encephalopathy, 2020.
13. Sanchez Fernandez I, Morales-Quezada JL, Law S, Kim P. Prognostic Value of Brain Magnetic Resonance Imaging in Neonatal Hypoxic-Ischemic Encephalopathy: A Meta-analysis. *J Child Neurol* 2017;32(13):1065-73. doi: 10.1177/0883073817726681 [published Online First: 2017/09/20]
14. Barkovich AJ, Hajnal BL, Vigneron D, et al. Prediction of neuromotor outcome in perinatal asphyxia: evaluation of MR scoring systems. *AJNR Am J Neuroradiol* 1998;19(1):143-9. [published Online First: 1998/02/12]
15. Martinez-Biarge M, Diez-Sebastian J, Kapellou O, et al. Predicting motor outcome and death in term hypoxic-ischemic encephalopathy. *Neurology* 2011;76(24):2055-61. doi: 10.1212/WNL.0b013e31821f442d [published Online First: 2011/06/15]
16. Martinez-Biarge M, Bregant T, Wusthoff CJ, et al. White matter and cortical injury in hypoxic-ischemic encephalopathy: antecedent factors and 2-year outcome. *J Pediatr* 2012;161(5):799-807. doi: 10.1016/j.jpeds.2012.04.054 [published Online First: 2012/06/12]
17. Goergen SK, Ang H, Wong F, et al. Early MRI in term infants with perinatal hypoxic-ischaemic brain injury: interobserver agreement and MRI predictors of outcome at 2 years. *Clin Radiol* 2014;69(1):72-81. doi: 10.1016/j.crad.2013.09.001 [published Online First: 2013/11/12]
18. Azzopardi D, Chew AT, Deierl A, et al. Prospective qualification of early cerebral biomarkers in a

- randomised trial of treatment with xenon combined with moderate hypothermia after birth asphyxia. *EBioMedicine* 2019;47:484-91. doi: 10.1016/j.ebiom.2019.08.034 [published Online First: 2019/08/28]
19. Murray DM, O'Connor CM, Ryan CA, et al. Early EEG Grade and Outcome at 5 Years After Mild Neonatal Hypoxic Ischemic Encephalopathy. *Pediatrics* 2016;138(4) doi: 10.1542/peds.2016-0659 [published Online First: 2016/09/22]
 20. Walsh BH, Neil J, Morey J, et al. The Frequency and Severity of Magnetic Resonance Imaging Abnormalities in Infants with Mild Neonatal Encephalopathy. *J Pediatr* 2017;187:26-33 e1. doi: 10.1016/j.jpeds.2017.03.065 [published Online First: 2017/05/10]
 21. Kilby MD. The role of next-generation sequencing in the investigation of ultrasound-identified fetal structural anomalies. *BJOG* 2021;128(2):420-29. doi: 10.1111/1471-0528.16533 [published Online First: 2020/09/26]
 22. Griffiths PD, Brackley K, Bradburn M, et al. Anatomical subgroup analysis of the MERIDIAN cohort: failed commissuration. *Ultrasound Obstet Gynecol* 2017;50(6):753-60. doi: 10.1002/uog.17502 [published Online First: 2017/04/25]
 23. Griffiths PD, Bradburn M, Campbell MJ, et al. Use of MRI in the diagnosis of fetal brain abnormalities in utero (MERIDIAN): a multicentre, prospective cohort study. *Lancet* 2017;389(10068):538-46. doi: 10.1016/S0140-6736(16)31723-8 [published Online First: 2016/12/19]
 24. Vaughn JA, Goncalves LF, Cornejo P. Intrauterine and Perinatal Infections. *Clin Perinatol* 2022;49(3):751-70. doi: 10.1016/j.clp.2022.05.008 [published Online First: 2022/09/17]
 25. Khalil A, Jones C, Ville Y. Congenital cytomegalovirus infection: management update. *Curr Opin Infect Dis* 2017;30(3):274-80. doi: 10.1097/QCO.0000000000000368 [published Online First: 2017/03/25]
 26. Diogo MC, Glatte S, Binder J, et al. The MRI spectrum of congenital cytomegalovirus infection. *Prenat Diagn* 2020;40(1):110-24. doi: 10.1002/pd.5591 [published Online First: 2019/12/06]
 27. de Vries LS, Gunardi H, Barth PG, et al. The spectrum of cranial ultrasound and magnetic resonance imaging abnormalities in congenital cytomegalovirus infection. *Neuropediatrics* 2004;35(2):113-9. doi: 10.1055/s-2004-815833 [published Online First: 2004/05/06]
 28. de Vries LS. Viral Infections and the Neonatal Brain. *Semin Pediatr Neurol* 2019;32:100769. doi: 10.1016/j.spen.2019.08.005 [published Online First: 2019/12/10]
 29. Sullivan G, Galdi P, Cabeza MB, et al. Interleukin-8 dysregulation is implicated in brain dysmaturation following preterm birth. *Brain Behav Immun* 2020;90:311-18. doi: 10.1016/j.bbi.2020.09.007 [published Online First: 2020/09/10]
 30. National Institute of Health and Care Excellence. Jaundice in newborn babies (CG98), 2010 updated in 2016.
 31. Gkoltsiou K, Tzoufi M, Counsell S, et al. Serial brain MRI and ultrasound findings: relation to gestational age, bilirubin level, neonatal neurologic status and neurodevelopmental outcome in infants at risk of kernicterus. *Early Hum Dev* 2008;84(12):829-38. doi: 10.1016/j.earlhumdev.2008.09.008 [published Online First: 2008/10/15]
 32. Shah R, Harding J, Brown J, McKinlay C. Neonatal Glycaemia and Neurodevelopmental Outcomes: A Systematic Review and Meta-Analysis. *Neonatology* 2019;115(2):116-26. doi: 10.1159/000492859 [published Online First: 2018/11/09]
 33. De Angelis LC, Brigati G, Polleri G, et al. Neonatal Hypoglycemia and Brain Vulnerability. *Front Endocrinol (Lausanne)* 2021;12:634305. doi: 10.3389/fendo.2021.634305 [published Online First: 2021/04/03]
 34. British Association of Perinatal Medicine. Identification and Management of Neonatal Hypoglycaemia in the Full Term Infant - A BAPM Framework of Practice, 2017.
 35. Burns CM, Rutherford MA, Boardman JP, Cowan FM. Patterns of cerebral injury and neurodevelopmental outcomes after symptomatic neonatal hypoglycemia. *Pediatrics* 2008;122(1):65-74. doi: 10.1542/peds.2007-2822 [published Online First: 2008/07/04]

36. Boardman JP, Wusthoff CJ, Cowan FM. Hypoglycaemia and neonatal brain injury. *Arch Dis Child Educ Pract Ed* 2013;98(1):2-6. doi: 10.1136/archdischild-2012-302569 [published Online First: 2012/10/23]
37. Lamlahi R, Latal B. Neurodevelopmental outcome of children with congenital heart disease. *Handb Clin Neurol* 2019;162:329-45. doi: 10.1016/B978-0-444-64029-1.00016-3 [published Online First: 2019/07/22]
38. Marino BS, Lipkin PH, Newburger JW, et al. Neurodevelopmental outcomes in children with congenital heart disease: evaluation and management: a scientific statement from the American Heart Association. *Circulation* 2012;126(9):1143-72. doi: 10.1161/CIR.0b013e318265ee8a [published Online First: 2012/08/02]
39. Pierpont ME, Basson CT, Benson DW, Jr., et al. Genetic basis for congenital heart defects: current knowledge: a scientific statement from the American Heart Association Congenital Cardiac Defects Committee, Council on Cardiovascular Disease in the Young: endorsed by the American Academy of Pediatrics. *Circulation* 2007;115(23):3015-38. doi: 10.1161/CIRCULATIONAHA.106.183056 [published Online First: 2007/05/24]
40. Sun L, Macgowan CK, Sled JG, et al. Reduced fetal cerebral oxygen consumption is associated with smaller brain size in fetuses with congenital heart disease. *Circulation* 2015;131(15):1313-23. doi: 10.1161/CIRCULATIONAHA.114.013051 [published Online First: 2015/03/13]
41. Peyvandi S, Latal B, Miller SP, McQuillen PS. The neonatal brain in critical congenital heart disease: Insights and future directions. *Neuroimage* 2019;185:776-82. doi: 10.1016/j.neuroimage.2018.05.045 [published Online First: 2018/05/23]
42. Mebius MJ, Kooi EMW, Bilardo CM, Bos AF. Brain Injury and Neurodevelopmental Outcome in Congenital Heart Disease: A Systematic Review. *Pediatrics* 2017;140(1) doi: 10.1542/peds.2016-4055 [published Online First: 2017/06/14]
43. Khalil A, Suff N, Thilaganathan B, et al. Brain abnormalities and neurodevelopmental delay in congenital heart disease: systematic review and meta-analysis. *Ultrasound Obstet Gynecol* 2014;43(1):14-24. doi: 10.1002/uog.12526 [published Online First: 2013/06/06]
44. Owen M, Shevell M, Majnemer A, Limperopoulos C. Abnormal brain structure and function in newborns with complex congenital heart defects before open heart surgery: a review of the evidence. *J Child Neurol* 2011;26(6):743-55. doi: 10.1177/0883073811402073 [published Online First: 2011/05/26]
45. UK collaborative randomised trial of neonatal extracorporeal membrane oxygenation. UK Collaborative ECMO Trial Group. *Lancet* 1996;348(9020):75-82. [published Online First: 1996/07/13]
46. Boyle K, Felling R, Yiu A, et al. Neurologic Outcomes After Extracorporeal Membrane Oxygenation: A Systematic Review. *Pediatr Crit Care Med* 2018;19(8):760-66. doi: 10.1097/PCC.0000000000001612 [published Online First: 2018/06/13]
47. Polito A, Barrett CS, Wypij D, et al. Neurologic complications in neonates supported with extracorporeal membrane oxygenation. An analysis of ELSO registry data. *Intensive Care Med* 2013;39(9):1594-601. doi: 10.1007/s00134-013-2985-x [published Online First: 2013/06/12]
48. Rollins MD, Yoder BA, Moore KR, et al. Utility of neuroradiographic imaging in predicting outcomes after neonatal extracorporeal membrane oxygenation. *J Pediatr Surg* 2012;47(1):76-80. doi: 10.1016/j.jpedsurg.2011.10.016 [published Online First: 2012/01/17]
49. Glass P, Bulas DI, Wagner AE, et al. Severity of brain injury following neonatal extracorporeal membrane oxygenation and outcome at age 5 years. *Dev Med Child Neurol* 1997;39(7):441-8. doi: 10.1111/j.1469-8749.1997.tb07463.x [published Online First: 1997/07/01]
50. Melbourne L, Wien MA, Whitehead MT, et al. Risk Factors for Brain Injury in Newborns Treated with Extracorporeal Membrane Oxygenation. *Am J Perinatol* 2021;38(14):1557-64. doi: 10.1055/s-0040-1714208 [published Online First: 2020/07/17]
51. Farhat A, Li X, Huet B, et al. Routine Neuroimaging: Understanding Brain Injury in Pediatric Extracorporeal Membrane Oxygenation. *Crit Care Med* 2022;50(3):480-90. doi:

- 10.1097/CCM.00000000000005308 [published Online First: 2021/10/13]
52. Bulas DI, Glass P, O'Donnell RM, et al. Neonates treated with ECMO: predictive value of early CT and US neuroimaging findings on short-term neurodevelopmental outcome. *Radiology* 1995;195(2):407-12. doi: 10.1148/radiology.195.2.7536947 [published Online First: 1995/05/01]
53. Bulas D, Glass P. Neonatal ECMO: neuroimaging and neurodevelopmental outcome. *Semin Perinatol* 2005;29(1):58-65. doi: 10.1053/j.semperi.2005.02.009 [published Online First: 2005/06/01]
54. Cengiz P, Seidel K, Rycus PT, et al. Central nervous system complications during pediatric extracorporeal life support: incidence and risk factors. *Crit Care Med* 2005;33(12):2817-24. doi: 10.1097/01.ccm.0000189940.70617.c3 [published Online First: 2005/12/15]
55. Barrett CS, Bratton SL, Salvin JW, et al. Neurological injury after extracorporeal membrane oxygenation use to aid pediatric cardiopulmonary resuscitation. *Pediatr Crit Care Med* 2009;10(4):445-51. doi: 10.1097/PCC.0b013e318198bd85 [published Online First: 2009/05/20]
56. Wien MA, Whitehead MT, Bulas D, et al. Patterns of Brain Injury in Newborns Treated with Extracorporeal Membrane Oxygenation. *AJNR Am J Neuroradiol* 2017;38(4):820-26. doi: 10.3174/ajnr.A5092 [published Online First: 2017/02/18]
57. British Association of Perinatal Medicine. Perinatal management of extreme preterm birth before 27 weeks of gestation. A BAPM framework for practice, 2019.
58. Stewart AL, Thorburn RJ, Hope PL, et al. Ultrasound appearance of the brain in very preterm infants and neurodevelopmental outcome at 18 months of age. *Arch Dis Child* 1983;58(8):598-604. doi: 10.1136/ad.58.8.598 [published Online First: 1983/08/01]
59. Maalouf EF, Duggan PJ, Counsell SJ, et al. Comparison of findings on cranial ultrasound and magnetic resonance imaging in preterm infants. *Pediatrics* 2001;107(4):719-27. doi: 10.1542/peds.107.4.719 [published Online First: 2001/05/23]
60. De Vries LS, Van Haastert IL, Rademaker KJ, et al. Ultrasound abnormalities preceding cerebral palsy in high-risk preterm infants. *J Pediatr* 2004;144(6):815-20. doi: 10.1016/j.jpeds.2004.03.034 [published Online First: 2004/06/12]
61. Inder TE, de Vries LS, Ferriero DM, et al. Neuroimaging of the Preterm Brain: Review and Recommendations. *J Pediatr* 2021;237:276-87 e4. doi: 10.1016/j.jpeds.2021.06.014 [published Online First: 2021/06/20]
62. Hand IL, Shellhaas RA, Milla SS, et al. Routine Neuroimaging of the Preterm Brain. *Pediatrics* 2020;146(5) doi: 10.1542/peds.2020-029082 [published Online First: 2020/10/28]
63. Maalouf EF, Duggan PJ, Rutherford MA, et al. Magnetic resonance imaging of the brain in a cohort of extremely preterm infants. *J Pediatr* 1999;135(3):351-7. doi: 10.1016/s0022-3476(99)70133-2 [published Online First: 1999/09/15]
64. Dyet LE, Kennea N, Counsell SJ, et al. Natural history of brain lesions in extremely preterm infants studied with serial magnetic resonance imaging from birth and neurodevelopmental assessment. *Pediatrics* 2006;118(2):536-48. doi: 10.1542/peds.2005-1866 [published Online First: 2006/08/03]
65. Inder TE, Wells SJ, Mogridge NB, et al. Defining the nature of the cerebral abnormalities in the premature infant: a qualitative magnetic resonance imaging study. *J Pediatr* 2003;143(2):171-9. doi: 10.1067/S0022-3476(03)00357-3 [published Online First: 2003/09/13]
66. Cornette LG, Tanner SF, Ramenghi LA, et al. Magnetic resonance imaging of the infant brain: anatomical characteristics and clinical significance of punctate lesions. *Arch Dis Child Fetal Neonatal Ed* 2002;86(3):F171-7. doi: 10.1136/fn.86.3.f171 [published Online First: 2002/04/30]
67. De Vries LS, Groenendaal F, van Haastert IC, et al. Asymmetrical myelination of the posterior limb of the internal capsule in infants with periventricular haemorrhagic infarction: an early predictor of hemiplegia. *Neuropediatrics* 1999;30(6):314-9. doi: 10.1055/s-2007-973511 [published Online First: 2000/03/08]
68. Tam EW, Rosenbluth G, Rogers EE, et al. Cerebellar hemorrhage on magnetic resonance imaging

- in preterm newborns associated with abnormal neurologic outcome. *J Pediatr* 2011;158(2):245-50. doi: 10.1016/j.jpeds.2010.07.049 [published Online First: 2010/09/14]
69. Guillot M, Sebastianski M, Lemyre B. Comparative performance of head ultrasound and MRI in detecting preterm brain injury and predicting outcomes: A systematic review. *Acta Paediatr* 2021;110(5):1425-32. doi: 10.1111/apa.15670 [published Online First: 2020/11/19]
 70. Steggerda SJ, Leijser LM, Wiggers-de Bruine FT, et al. Cerebellar injury in preterm infants: incidence and findings on US and MR images. *Radiology* 2009;252(1):190-9. doi: 10.1148/radiol.2521081525 [published Online First: 2009/05/08]
 71. Villamor-Martinez E, Fumagalli M, Alomar YI, et al. Cerebellar Hemorrhage in Preterm Infants: A Meta-Analysis on Risk Factors and Neurodevelopmental Outcome. *Front Physiol* 2019;10:800. doi: 10.3389/fphys.2019.00800 [published Online First: 2019/07/12]
 72. Limperopoulos C, Du Plessis AJ, Volpe JJ. Cerebellar hemorrhage. Volpe's Neurology of the Newborn. Philadelphia: Elsevier 2018:623-36.
 73. Edwards AD, Redshaw ME, Kennea N, et al. Effect of MRI on preterm infants and their families: a randomised trial with nested diagnostic and economic evaluation. *Arch Dis Child Fetal Neonatal Ed* 2018;103(1):F15-F21. doi: 10.1136/archdischild-2017-313102 [published Online First: 2017/10/11]
 74. Woodward LJ, Anderson PJ, Austin NC, et al. Neonatal MRI to predict neurodevelopmental outcomes in preterm infants. *N Engl J Med* 2006;355(7):685-94. doi: 10.1056/NEJMoa053792 [published Online First: 2006/08/18]
 75. Valkama AM, Paakko EL, Vainionpaa LK, et al. Magnetic resonance imaging at term and neuromotor outcome in preterm infants. *Acta Paediatr* 2000;89(3):348-55. [published Online First: 2000/04/20]
 76. de Vries LS, van Haastert IC, Benders MJ, Groenendaal F. Myth: cerebral palsy cannot be predicted by neonatal brain imaging. *Semin Fetal Neonatal Med* 2011;16(5):279-87. doi: 10.1016/j.siny.2011.04.004 [published Online First: 2011/06/04]
 77. Mirmiran M, Barnes PD, Keller K, et al. Neonatal brain magnetic resonance imaging before discharge is better than serial cranial ultrasound in predicting cerebral palsy in very low birth weight preterm infants. *Pediatrics* 2004;114(4):992-8. doi: 10.1542/peds.2003-0772-L [published Online First: 2004/10/07]
 78. Nongena P, Ederies A, Azzopardi DV, Edwards AD. Confidence in the prediction of neurodevelopmental outcome by cranial ultrasound and MRI in preterm infants. *Arch Dis Child Fetal Neonatal Ed* 2010;95(6):F388-90. doi: 10.1136/adc.2009.168997 [published Online First: 2010/09/28]
 79. Setanen S, Haataja L, Parkkola R, et al. Predictive value of neonatal brain MRI on the neurodevelopmental outcome of preterm infants by 5 years of age. *Acta Paediatr* 2013;102(5):492-7. doi: 10.1111/apa.12191 [published Online First: 2013/02/13]

Appendix 1a: Suggested key sequences and parameters for neonatal MR scans at 1.5T

Sequence	Suggested Parameters
Core Protocol	
Axial FSE T2 Coronal FSE T2	TR 4500 TE 130
Axial DWI	B 700 / 800 TR 7780 TE minimum
Axial TIR	TR 3500 TE minimum TI 1036
Volume T1	TR 13.9 TE 6.2
Axial GE or SWI	GRE T2 * TR 980 TE6.0
Optional Sequences	
Proton Density	TR 4500 TE 30
MRV	
MRA	
MRS	TE 144

Appendix 1b: Suggested key sequences and parameters for neonatal MR scans at 3.0T

Sequence	Suggested Parameters
Core Protocol	
Axial FSE T2 Coronal FSE T2	TR 12,000 TE 156
Axial DWI (quick)	B 750 TR shortest TE 49
Volume T1 MP Rage	TR 11 TE 4.6
SWI	TR 32 TE 25
Optional Sequences	
MRV (PCA)	TR shortest TE shortest
MRA	TR shortest TE 8
MRS	TE 144 and 288

FSE: fast spin echo; TR: repetition time; TE: echo time; DWI: diffuse weighted imaging; TIR: true inversion recovery; GE: gradient echo; SWI: susceptibility weighted images; MRV: magnetic resonance venography; MRA: magnetic resonance angiography; MRS: magnetic resonance spectroscopy.

These are suggested sequences and parameters; please refer to the manufacturer's neonatal exam card for specific parameters relating to specific scanners.

Appendix 2: Example Reporting Proforma

Date of report:

NEONATAL MRI BRAIN REPORT

NAME:

REFERRER:

D.O.B:

D.O.S:

NHS number:

Clinical Details:

GA:

Birth weight (g):

OFC (cm):

Apgar Scores: @1, @5, @10 Arterial pH

Venous pH

Relevant family history:

Antenatal history:

Labour and Delivery:

Condition at Birth:

Apgar scores.

Cord pH

Placental histology:

Presenting Issues:

CFM/EEG:

Cranial US:

Metabolic investigations:

Infection screen:

Current neurology:

Current feeding mode:

Discharged to home:

To referring hospital:

Age at scan: weeks PMA

MRI SUMMARY:

Findings:

Aetiology:

Suggested further investigations:

NAME:

Images were obtained with: e.g. *T1-, T2-weighted, diffusion-weighted, MRV, MRA and SWI*

Bi parietal diameter = mm

Occipitofrontal diameter = mm

MR derived OFC = cm

Cortex:

Hippocampi:

Basal ganglia and thalami:

Posterior limb of the internal capsule:

White matter:

Corpus callosum:

Cerebellum:

Brainstem:

Extracerebral space:

Ventricles	Lateral:
	3rd:
	4th:
	Aqueduct:

Germinal matrix:

Cavum Septum Pellucidum:

Myelination:

Pituitary gland :

Orbits:

Optic nerves:

Specific sequence details

Diffusion ADC map:

SWI:

FLAIR:

MRV:

MRA:

Appendix 3: Development of the framework

The framework was conceived as an update on the British Association of Perinatal Medicine (BAPM) 2016 Framework: 'Fetal and Neonatal Brain Magnetic Resonance Imaging: Clinical Indications, Acquisitions and Reporting.' The proposal for the update was initiated by the chair of the 2016 framework (TA) and was agreed by the BAPM board.

Recruitment to BAPM working groups follows a standard procedure, the Chair and Chief Executive agree the list of representatives that are needed and an advert is sent out asking BAPM members and stakeholders to apply. Trainee and parent representatives are always included. Applications are then anonymised before being considered by the Working Group Chair. The members of the working group for the 2016 framework were also invited to contribute to this update and a number agreed to contribute.

The first meeting of the working group was on 14 January 2021. At this meeting it was agreed that formal endorsement from the British Paediatric Neurology Association (BPNA), British Society of Neuroradiologists (BSNR) and the Society of Radiographers (SoR) would be desirable. Therefore, the working group was expanded by additional members from these societies. At a subsequent meeting in November 2021, it was agreed to limit the scope of the framework to neonatal brain imaging and not include fetal brain imaging as it was decided this would be better served as a separate framework to include whole body fetal imaging.

A framework for practice is not meant to be a comprehensive systematic review of the literature, nor a didactic guideline for management, but a document which distils the current evidence of practice obtained through standard literature searches and provides recommendations for implementation within the specific context of the UK National Health Service.

Individual members of the group were responsible for drafting different sections of the framework based on literature review including existing guidelines as well as clinical experience. These were then compiled by the chair and the document circulated to the whole group for comment and edited accordingly. A final draft was put out to consultation on 23 January 2023 for six weeks. The consultation process involved circulating the document to members and stakeholders of BAPM as well as circulating to the collaborating organisations (BPNA, BSNR and SoR). The chair compiled responses to the reviews of the document and following consultation with the group members a final version of the framework was agreed upon for publication taking into account feedback from the peer review.



BAPM

Leading Excellence in Perinatal Care

**This document was produced by the
British Association of Perinatal Medicine (BAPM).**

BAPM a membership organisation that is here to support all those involved in perinatal care to optimise their skills and knowledge, deliver and share high-quality safe and innovative practice, undertake research, and speak out for babies and their families.

We are a professional association of neonatologists, paediatricians, obstetricians, nurses, midwives, trainees, network managers and other health professionals dedicated to shaping the delivery and improving the standard of perinatal care in the UK.

Our vision is for every baby and their family to receive the highest standard of perinatal care. Join us today.

www.bapm.org/join

British Association of Perinatal Medicine (BAPM)
is registered in England & Wales
under charity number 1199712 at
5-11 Theobalds Road, London, WC1X 8SH